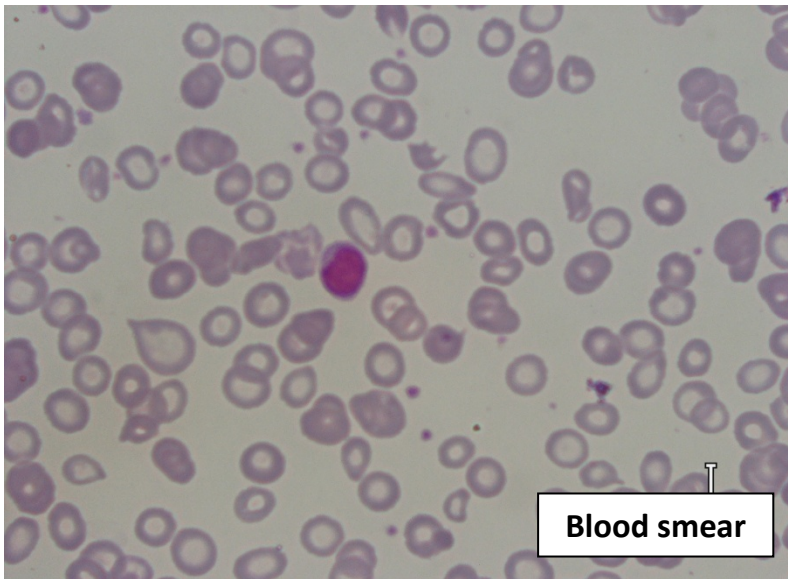
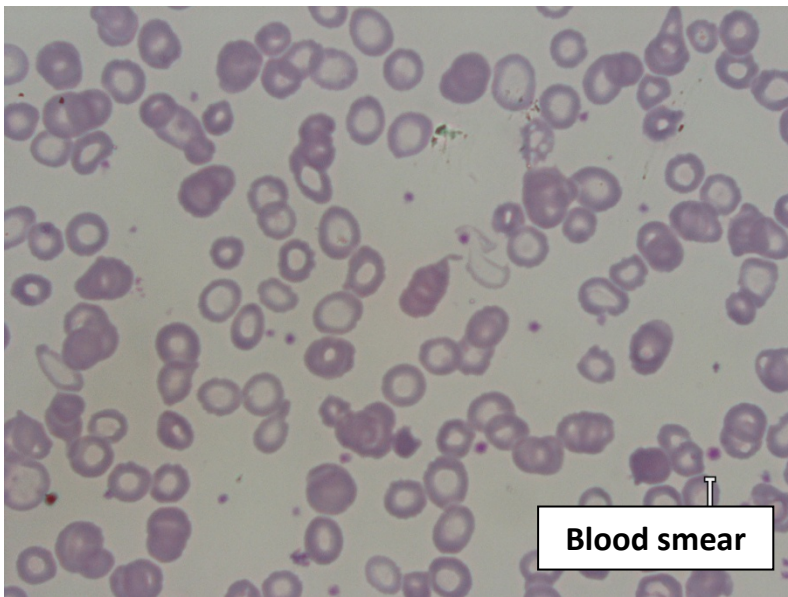




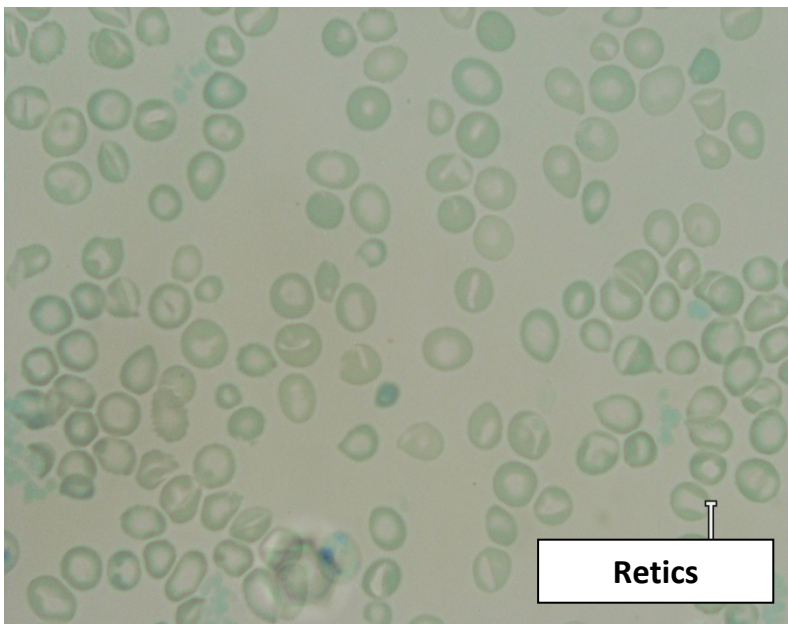
- (Ref No 222)
- Male of 8 month age, Pathan
- Abdominal distention
- Liver edge palpable , spleen 4 cms



Blood smear



Blood smear

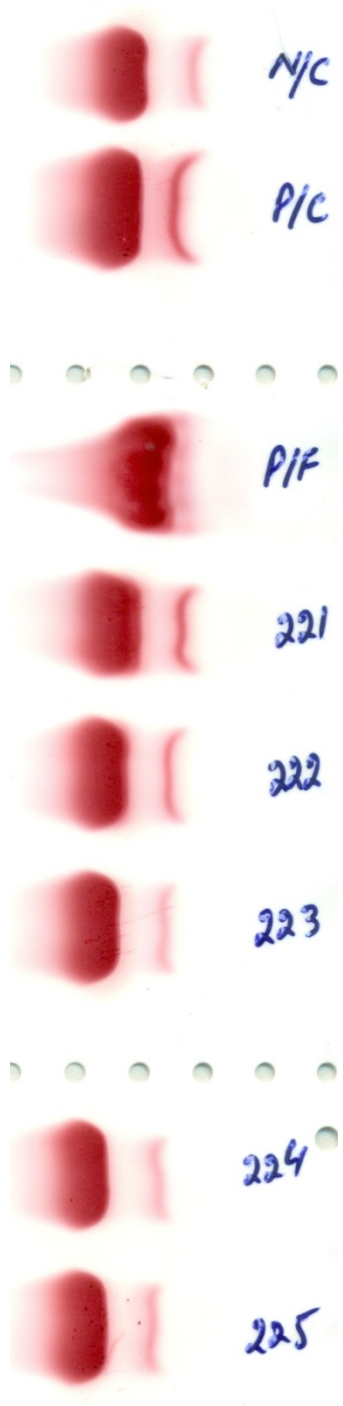


Retics

Blood counts in the patient and his parents

Parameter		Patient 5(222)	Father	Mother
RCC	x10 ¹² /L	3.26	7.22	5.79
Hb	g/dl	6.4	13.4	11.7
MCV	fl	69.3	61.8	68.2
MCH	pg	19.6	18.6	20.2
MCHC	g/dl	28.3	30	29.5
RDW				
Retics	%	1.8		
NRBCs	/100 wbc	1		
TLC	x10 ⁹ /L	14.3	6.6	9.2
Platelets	x10 ⁹ /L	186	341	538

Hb Electrophoresis



Opinion

- Patient: Inconclusive result
- Advised PCR for common and uncommon mutations in region
- You are requested to suggest mutations